

Cancer in Wild Animals


Printed from <https://www.cancerquest.org/cancer-biology/cancer-wild-animals> on 04/19/2024

Cancer seems to affect all animals, from anteaters to zebras. Much less is known about the cancers that affect wild animals, in part because it is hard to study. Animals move around and may not be easily observed for long periods of time. The cancers that have been studied are very interesting and will certainly prove useful in the study of human cancer. As an example, Tasmanian devils have a type of cancer that can be spread from animal to animal by biting!

- [Dinosaur cancer](#)
- [Tasmanian Devil cancer](#)
- [Cancer in wild fish](#)
- [Naked mole rats](#)
- [Clam cancer](#)
- [Tapeworm cancer \(in human host\)](#)

Cancer in Dinosaurs

Dinosaur.jpg



Cancer is a disease that has been around for millions of years. In a 2003 study, researchers used fluoroscopy and computed tomography (CT) to screen over 10,000 dinosaur vertebrae specimens for tumors. They found tumors in approximately 3% of the duck-billed dinosaur (Cretaceous hadrosaurs) specimens, but did not find tumors in any other dinosaur species. The tumors included hemangiomas, desmoplastic fibroma, and osteoblastoma. [1](#)

In an earlier study conducted in 1999, metastatic cancer was found in only 1 out of 548 Edmontosaurus vertebrae sampled and was absent in all remaining samples. Hemangioma was present in 20 out of 669 Edmontosaurus vertebrae sampled and was absent in all 286 Corythosaurus vertebrae sampled as well as all 7,475 sauropods, ceratopsians, stegosaurs, theropoda, ornithomimids, and ankylosaurs vertebrae sampled. [2](#) [3](#)

Researchers have emphasized that, in some cases, the absence and presence of certain cancers in some dinosaur species but not in others may be due to inadequate sample size rather than species specificity. The statistically significant higher occurrence of hemangiomas found in hadrosaurs than in other dinosaur species suggests a possible genetic or environmental basis behind the pattern of tumor incidence. An example of an environmental factor could be the carcinogenic tannins, phenols, and resins found in the leaves consumed by these types of dinosaurs. [1](#) [3](#)

Tasmanian Devil Facial Tumor Disease

Tasmanian Devil



In 2008, the International Union for Conservation of Nature officially declared the Tasmanian devil an endangered species (<http://www.iucnredlist.org/details/40540/0>).

The animals were driven to extinction on the Australian mainland thousands of years ago, after humans introduced dingoes to the continent. The remainder of the wild population has since inhabited the Australian island-state of Tasmania. In the mid 1990's the population reached an estimated 150,000 devils. [4](#) Today, however, the animals are plagued by an infectious cancer known as Tasmanian devil facial tumor disease (DFTD). Since the emergence of the disease in 1996, the population has declined by more than 60%. [5](#) As a result, what was once the largest surviving population of marsupial carnivores is now threatened with extinction.

This type of cancer is **very unusual**. The great majority of cancer cases in humans and animals arise from a series of mutations in a single precursor cell and its daughter cells. The process occurs over a period of years and does not involve contact with any other individuals. DFTD develops differently. It's transmitted from animal to animal and the cancer cells themselves are the infectious agent.

Researchers describe this phenomenon as allograft transmission⁶. An allograft is the term for the transfer of cells/tissue from one individual to another (of the same species). An example in humans is organ transplantation. The movement of cancer cells between animals has been confirmed by cellular and molecular studies. A normal devil cell contains 14 chromosomes⁶. DFTD tumor cells contain several very distinctive genetic changes and have only 13 chromosomes. Importantly, the tumors from every animal tested appear identical⁶. Researchers in Tasmania also found a devil with an unusual chromosomal abnormality in its **non-tumorous** tissue that did not appear in its tumor cells⁶. These findings strongly suggest that the cancer did not arise from the animals' own cells.


A cancer similar to DFTD occurs in dogs, and is known as Canine Transmissible Venereal Tumor (CTVT). The immune system of dogs is capable of overcoming the disease, but devils do not seem to be able to do so. Researchers have hypothesized that low genetic diversity among Tasmanian devils results in close kinship and reduces their immune responses^{7 8 9 10}. As a result, transplanted cancer cells are more likely to survive, grow, and spread.

Transmission can occur by biting, feeding on the same material, aggressive mating, and other social interactions. DFTD tumors mostly form on the face and/or in the oral cavity. The cancer can also metastasize to other areas of the body. Nearly 100% of infected devils die within 6 months of the onset of clinical signs⁶. Death results from an inability to feed, secondary infection, or symptoms associated with metastases.

Efforts are also being made to capture and relocate healthy animals to repopulate disease-free areas. The Tasmanian government is working with conservation specialists to reduce the impact of the disease. On September 26, 2015, as part of the Wild Devil Recovery Project funded by the Tasmanian government, 19 Tasmanian devils were given vaccines against DFTD and released into Narawntapu National Park in northern Tasmania. These devils were formerly kept separate from wild devils but have now been released into the wild population. Researchers will monitor these devils to gauge the vaccine's effectiveness in preventing DFTD. If this vaccine against DFTD is successful, it has the potential to significantly reduce the spread of the disease.

The devils may also be fighting back against the cancer on their own, in a very different way - evolution. Biologists studying the devils have found that they may be developing resistance against DFTD. Animals that are resistant have more/healthier offspring. This causes genetic changes that provide protection against the disease to become more common in the population. Researchers have been surprised at the speed at which the changes are occurring, and the number of genes involved^{11 12}. Whether the changes will happen quickly enough to save the devils from extinction is not known.

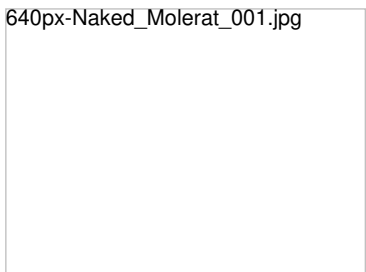
Cancer in Wild Fish



The image above shows sick coral trout. a) a fish with a large melanoma on its side, b) a fish that is almost entirely covered in melanoma, c) close-up of normal skin, d) close-up of melanoma on the skin of a fish. The image on the right is taken from the PLoS article cited above.

In August of 2012 an article was published that described the discovery of melanoma affecting a population of wild fish. The fish, *Plectropomus leopardus*, commonly called coral trout, live along the Great Barrier reef. Because the reef is located directly under the largest known ozone 'hole', it is thought that the cancer is due to increased exposure of the fish to ultraviolet (UV) radiation. Ozone normally absorbs the damaging UV rays, but ozone depletion allows the rays to reach the surface of the earth (and the fish). No other causes of the cancer were identified in the study. UV light is the single greatest risk factor for the development of skin cancer (including melanoma) in humans¹³.

Cancer in Naked Mole Rats



Naked mole rats live long lives, up to thirty years¹⁴. Though cancer incidence increases with age, cancer was not observed in this species, making it an

attractive model organism for cancer researchers. By studying naked mole rats, researchers hoped to discover the keys to cancer resistance; if they found out what made these organisms so resistant to cancer, they could use that information in the human fight against the disease.

Ironically, cases of cancer have been recently reported in naked mole rats.[15](#) [16](#) These case reports indicate that naked mole rats are not cancer-proof, though they do not develop cancer at rates predicted by their long lifespan.

One reason for this could be a carbohydrate polymer, hyaluronic acid, which was found to be much larger in naked mole rats than in other mammals.[17](#) Laboratory experiments with breast cancer cells showed that culturing them with hyaluronic acid caused the cells to die by apoptosis.[18](#)

[Learn more about apoptosis in cancer.](#)

Cancer in Clams




In 2015, an international team of researchers reported on a cancer that is able to kill large numbers of clams (and other marine bivalves). The clams develop a type of leukemia. It affects cells that live in their hemolymph, the equivalent of human blood. The disease is severe, and affected clams usually die.

Importantly, it has been shown that the cancer cells can float away from an affected clam to invade neighboring animals, spreading the disease. The fact that the cancer can spread means it has potentially huge economic and environmental impacts. The seafood industry relies on large farms to raise clams, and they are at risk due to this disease.[19](#)

Tapeworm Cancer (In a Human Host)

h-nana-tapeworm.jpeg



In a **very unusual** case, a man infected with HIV was found to also have what appeared to be cancer. Upon closer inspection, it was determined that the cancer cells were actually tapeworm cells. Apparently, the man was invaded by cells from a tapeworm, and the tapeworm cells began to divide and form tumorous growths. Researchers believe that the man was susceptible due to his extremely weakened condition.[20](#)

- [1](#) [a](#) [b](#) Rothschild BM, Tanke DH, Helbling M 2nd, Martin LD. Epidemiologic study of tumors in dinosaurs. *Naturwissenschaften*. 2003 Nov;90(11):495-500. Epub 2003 Oct 14. [\[PUBMED\]](#)
- [2](#) Rothschild BM, Witzke BJ, Hershkovitz I. Metastatic cancer in the Jurassic. *Lancet*. 1999 Jul 31;354(9176):398. [\[PUBMED\]](#)
- [3](#) [a](#) [b](#) Rehemtulla A. Dinosaurs and ancient civilizations: reflections on the treatment of cancer. *Neoplasia*. 2010 Dec;12(12):957-68. [\[PUBMED\]](#)
- [4](#) Hawkins et al., Emerging disease and population decline of an island endemic, the Tasmanian devil *Sarcophilus harrisii*, *Conserv*. 131 (2006), pp. 307-324.
- [5](#) Department of Primary Industries and Water (2008) Save the Tasmanian devil (www.tassiedevil.com.au) [\[http://www.tassiedevil.com.au/disease.html\]](http://www.tassiedevil.com.au/disease.html)
- [6](#) [a](#) [b](#) [c](#) [d](#) [e](#) A.M. Pearse and K. Swift, Allograph theory: Transmission of the devil facial-tumor disease, *Nature*. 439 (2006), pp. 549. [\[PUBMED\]](#)
- [7](#) R. Frankham et al., A Primer of Conservation Genetics, Cambridge University Press (2004). http://books.google.com/books?hl=en&lr=&id=mdEHpSmFVAIC&oi=fnd&pg=PA3&dq=%22Frankham%22+%22A+primer+of+conservation+genetics%22+&ots=7X_Tniotdo&sig=M-nYIFxNJRGXNYbZVzla2b8ekcU
- [8](#) P.W. Hedrick and S.T. Kalinowski, Inbreeding depression in conservation biology, *Annu. Rev. Ecol. Syst.* 31 (2000), pp. 139-162. [\[http://arjournals.annualreviews.org/doi/pdf/10.1146/annurev.ecolsys.31.1.139\]](http://arjournals.annualreviews.org/doi/pdf/10.1146/annurev.ecolsys.31.1.139)
- [9](#) S.J. O'Brien and J.F. Evermann, Interactive influence of infectious disease and genetic diversity in natural populations, *Trends Ecol. Eval.* 3 (1988), pp. 234-259.
- [10](#) S. Lachish, H. McCallum, and M. Jones, Demography, disease and the devil: life-history changes in a disease-affected population of Tasmanian devils (*Sarcophilus harrisii*), *Journal of Animal Ecology*. 78 (2009), pp.427-436.
- [11](#) Epstein, B., Jones, M., Hamede, R., Hendricks, S., McCallum, H., Murchison, E., et al (2016). Rapid evolutionary response to a transmissible cancer in Tasmanian devils. *Nature Communications*, 7, 12684. <http://doi.org/10.1038/ncomms12684> (Original work published December 2016) [\[PUBMED\]](#)
- [12](#) Stahlke, A., Epstein, B., Barbosa, S., Margres, M., Patton, A., Hendricks, S., et al (2021). Contemporary and historical selection in Tasmanian devils () support novel, polygenic response to transmissible cancer. *Proceedings. Biological Sciences*, 288(1951), 20210577. <http://doi.org/10.1098/rspb.2021.0577> (Original work published December 2021) [\[PUBMED\]](#)
- [13](#) Sweet M, Kirkham N, Bendall M, Currey L, Bythell J, et al. (2012) Evidence of Melanoma in Wild Marine Fish Populations. *PLoS ONE* 7(8): e41989. <http://www.plosone.org/article/info%3Adoi%2F10.1371%2Fjournal.pone.0041989>
- [14](#) Piersigilli A, Meyerholz DK. The "Naked Truth": Naked Mole-Rats Do Get Cancer. *Vet Pathol*. 2016 May;53(3):519-20. [\[PUBMED\]](#)
- [15](#) Delaney MA, Ward JM, Walsh TF, Chinnadurai SK, Kerns K, Kinsel MJ, Treuting PM. Initial Case Reports of Cancer in Naked Mole-rats (*Heterocephalus glaber*). 2016 May;53(3):691-6. [\[PUBMED\]](#)
- [16](#) Taylor KR, Milone NA, Rodriguez CE. Four Cases of Spontaneous Neoplasia in the Naked Mole-Rat (*Heterocephalus glaber*), A Putative Cancer-Resistant Species. *J Gerontol A Biol Sci Med Sci*. 2016 Apr 29. [\[PUBMED\]](#)

- [17](#)Tian, X., Azpurua, J., Hine, C., Vaidya, A., Myakishev-Rempel, M., Ablaeva, J., et al (2013). High-molecular-mass hyaluronan mediates the cancer resistance of the naked mole rat. *Nature*, 499(7458), 346-9. <http://doi.org/10.1038/nature12234> (Original work published July 2013) [[PUBMED](#)]
- [18](#)Zhao, Y., Qiao, S., Hou, X., Tian, H., Deng, S., Ye, K., et al (2019). Bioengineered tumor microenvironments with naked mole rats high-molecular-weight hyaluronan induces apoptosis in breast cancer cells. *Oncogene*, 38(22), 4297-4309. <http://doi.org/10.1038/s41388-019-0719-4> (Original work published December 2019) [[PUBMED](#)]
- [19](#)Metzger MJ, Reinisch C, Sherry J, Goff SP. Horizontal transmission of clonal cancer cells causes leukemia in soft-shell clams. 2015. *Cell*. Apr 9;161(2):255-63. [[PUBMED](#)]
- [20](#)Muehlenbachs A, Mathison BA, Olson PD. Malignant Transformation of *Hymenolepis nana* in a Human Host. *N Engl J Med*. 2016 Mar 31;374(13):1293-4. doi: 10.1056/NEJMc1600490.[[PUBMED](#)]